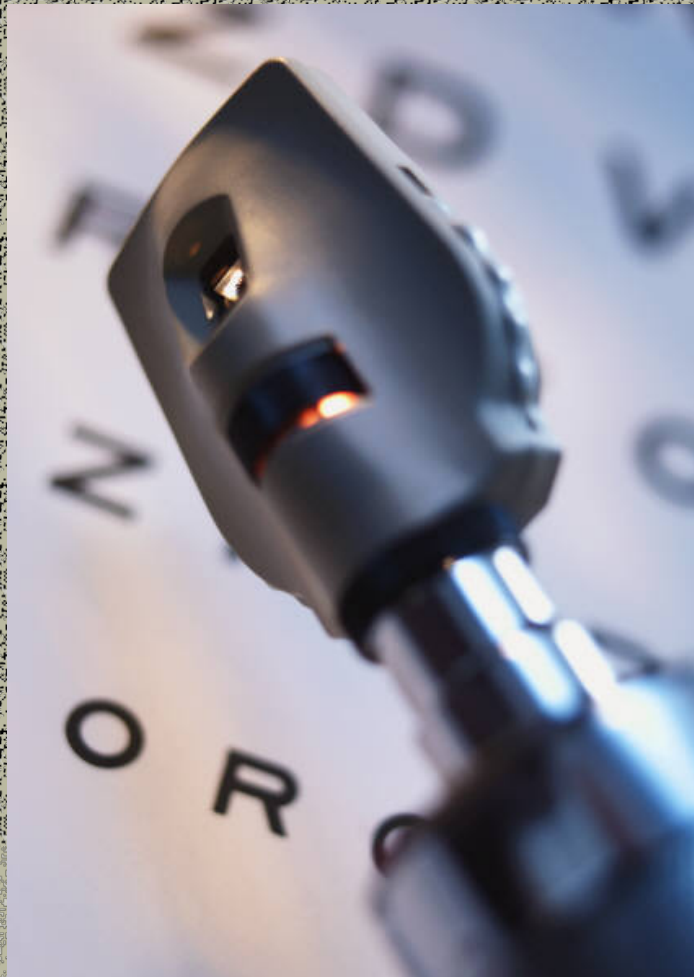

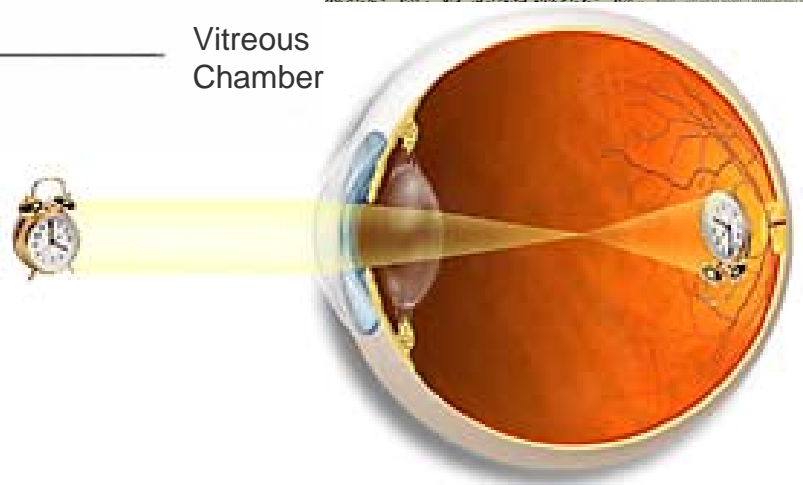
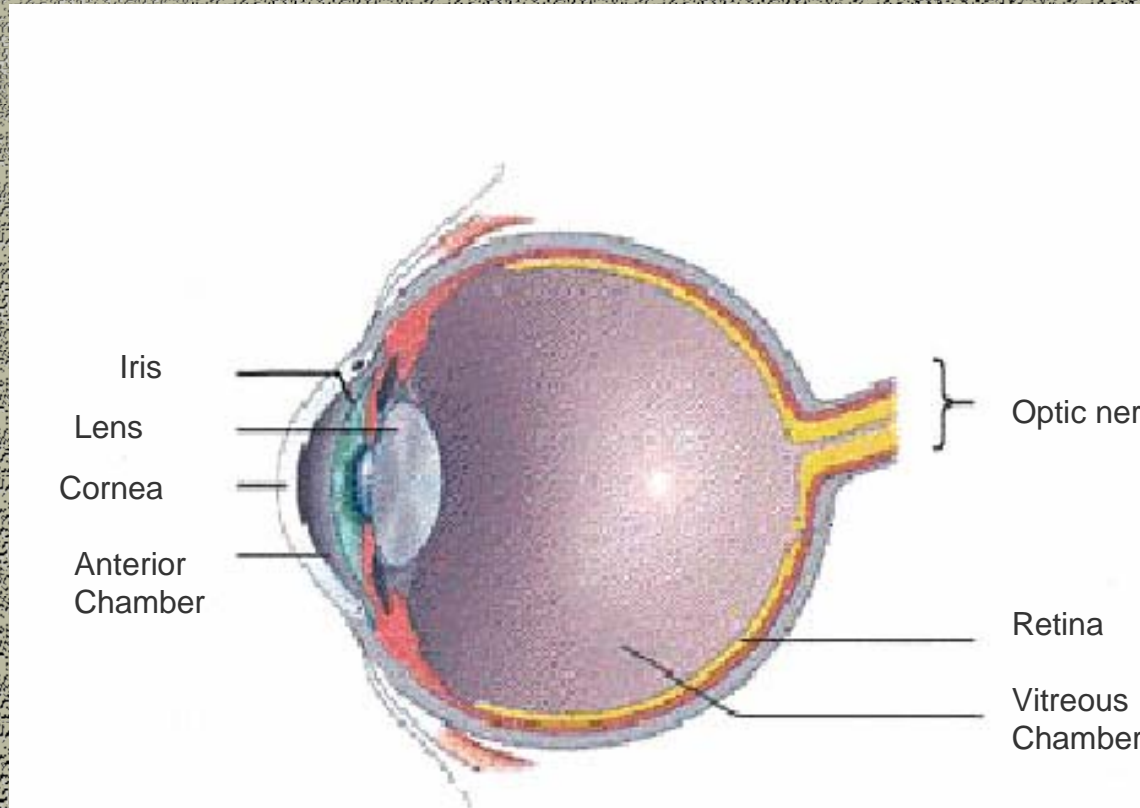


Diabetic Retinopathy





Anatomy of the Eye

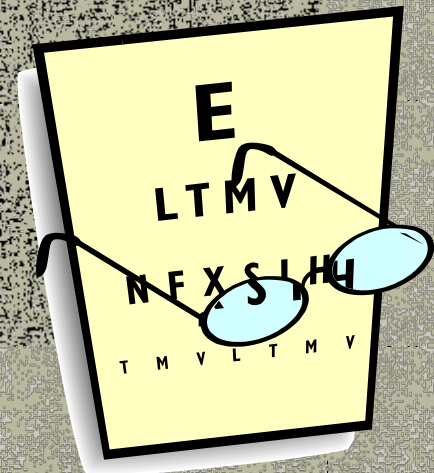


Normal Eye



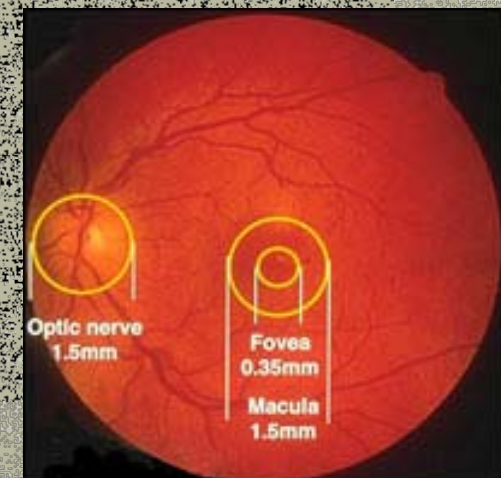
Diabetes Related Eye Problems

- Blurred vision and difficulty focusing are classic signs of newly diagnosed diabetes.
- Harmless – lasts 6–8 weeks
- Okay to buy cheap glasses to improve vision temporarily
- May recur with periods of poor control



What Is Retinopathy?

- Damage caused by diabetes to the small blood vessels of the eye.
- Commonest cause of blindness in the young adult
- It is treatable if diagnosed early





Key Points

- Have regular eye checkes in order to pick up any dammage early
- Don't wait until your vision is changed before you have a check
- Early eye dammage can very often be successfully treated
- Late dammage often cannot be treated



Retinopathy

- May be present in Type 2 patients at diagnosis
- 3 – 5 yrs after diagnosis in Type 1
- A normal visual acuity does not exclude retinopathy
- Visual impairment is rare in the early stages



Retinopathy: Prevalence

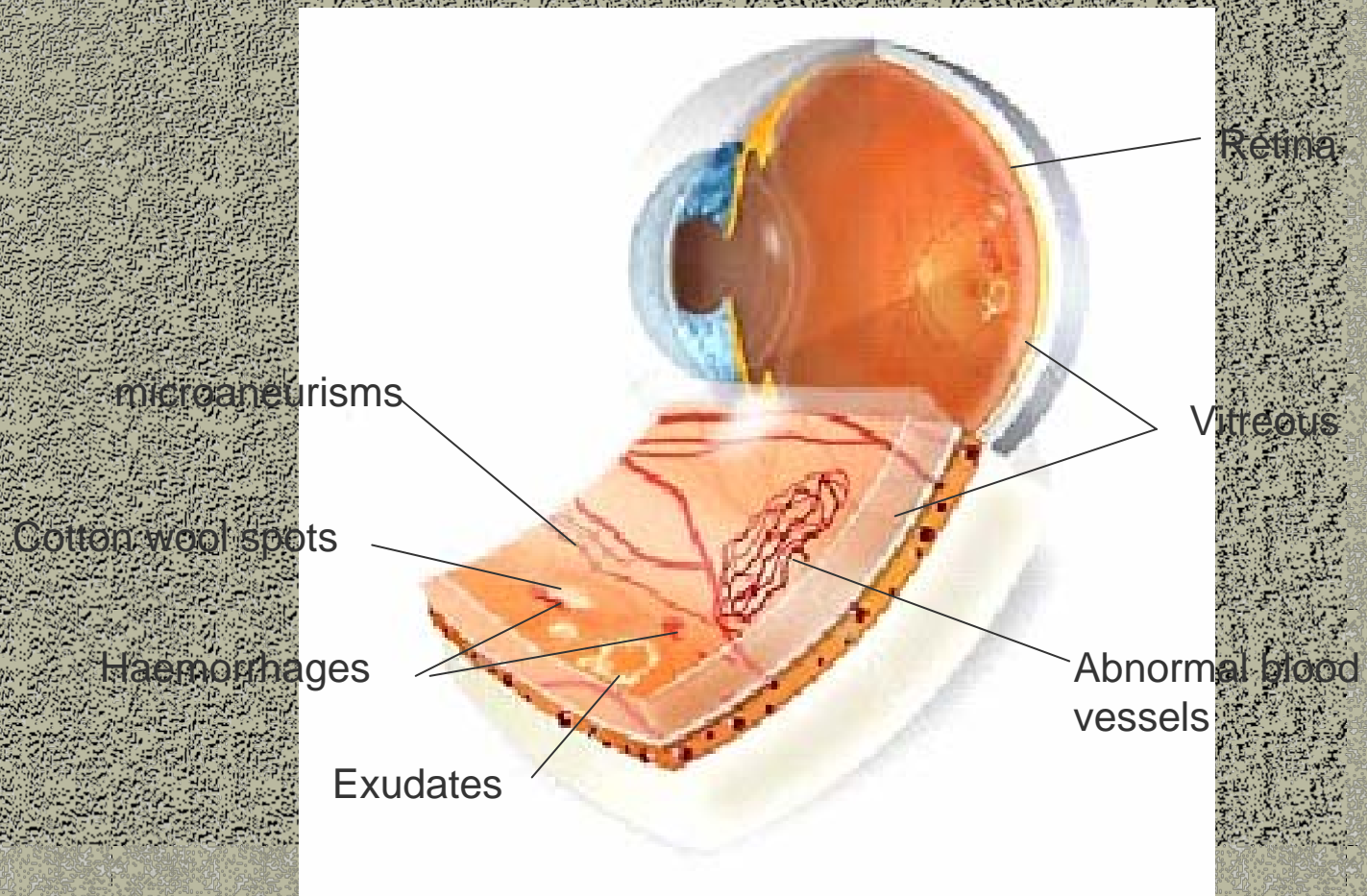
■ Type 2

- at diagnosis approx 6-39% have some form of retinopathy
- after 20 years almost 60% will have some form of retinopathy

- Does not cause vision loss unless it occurs near the macula

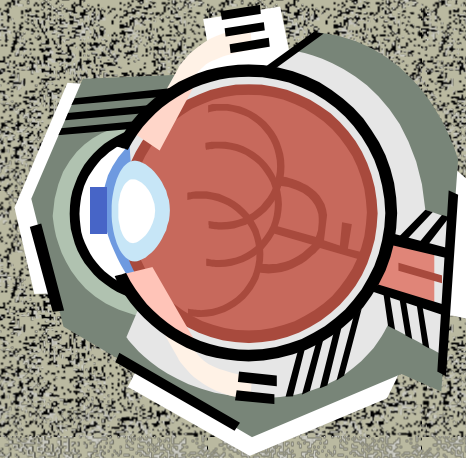


Pre-proliferative Retinopathy



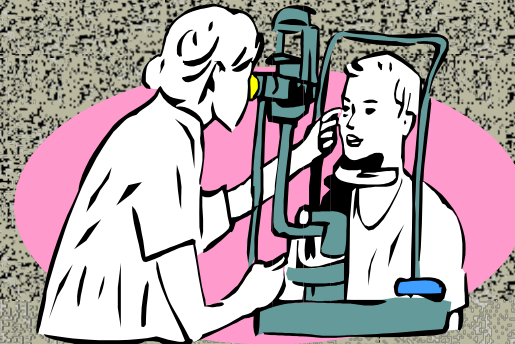
Background Retinopathy

- Small microaneurysms occur in the capillaries of the retina
- The vessels may leak → dot & blot haemorrhages and serous fluid (exudates)



Pre-proliferative Retinopathy

- The abnormal blood vessels become occluded
- Areas of retinal ischaemia (infarcts) develop
- Seen as “cottonwool” spots on the retina





Proliferative Retinopathy

- New vessels develop to resupply ischaemic areas
- They grow haphazardly and are not successful in improving blood supply
- Are fragile and bleed – floaters and cobwebs
- Large bleeds → black spots or total occlusion
- Bleeds are painless and usually clear within weeks




But.....

- Some bleeds do not resolve, requiring vitrectomy
- Scar tissue can form following a bleed
→ subsequent shrinkage ... retinal detachment



Diabetic Maculopathy

- Is most common in Type 2
- Damaged blood vessels leak a fatty exudate (Macula region)
- Visual acuity deteriorates, central vision may be lost
- Laser photocoagulation not effective in the late stages
- Regular testing of V.A. will help detection at an early stage





How is retinopathy treated?


- During the first three stages of diabetic retinopathy, no treatment is needed, unless you have macula oedema.
- To prevent progression of diabetic retinopathy, people with diabetes should control their levels of blood sugar, blood pressure, and blood cholesterol.



Laser Therapy

Laser therapy is used to seal up or control leaking fragile new blood vessels

Treating leaking and new vessels can prevent or delay further eye damage



Cataracts & Glaucoma

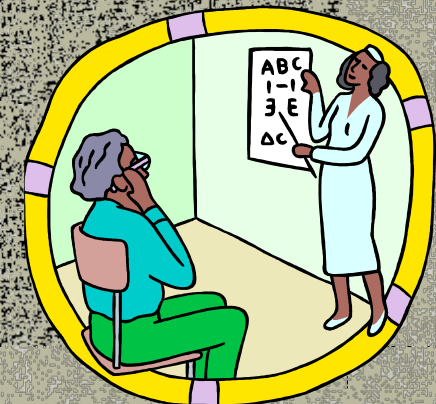
- These are not diabetes specific conditions...



- Cataracts however tend to occur at an earlier age in the diabetic popn
- The risk of developing glaucoma is enhanced in diabetes through damage to the blood vessels supplying the eye

Preserving Vision In Diabetes

- Minimise the risk by:-
 - good glycaemic control
 - control of B/P and lipids
- Detection of early changes:-
 - measure V.A. at least annually
 - retinal screening at least 2 yrly
- Urgent ophthalmological r/v if sudden reduction in vision occurs





Key Points

- Have regular eye checks in order to pick up any damage early
- Don't wait until your vision is changed before you have a check
- Early eye damage can very often be successfully treated
- Late damage often cannot be treated

